Female reproductive system

Practical

Dr. Nassam Emad Daim

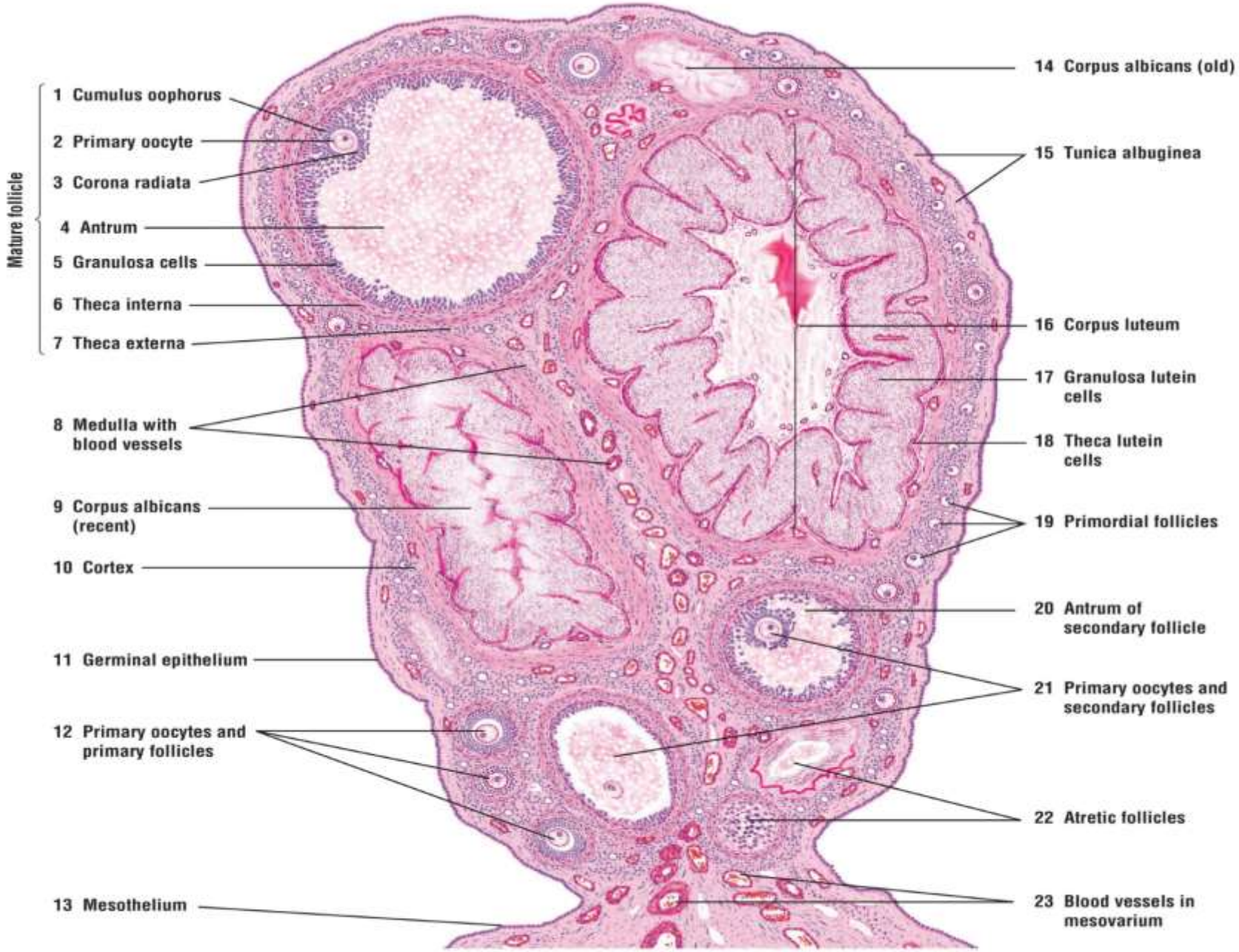

FIGURE 21.1 ■ Ovary: different stages of follicular development (panoramic view). Stain: hematoxylin and eosin. Low magnification.

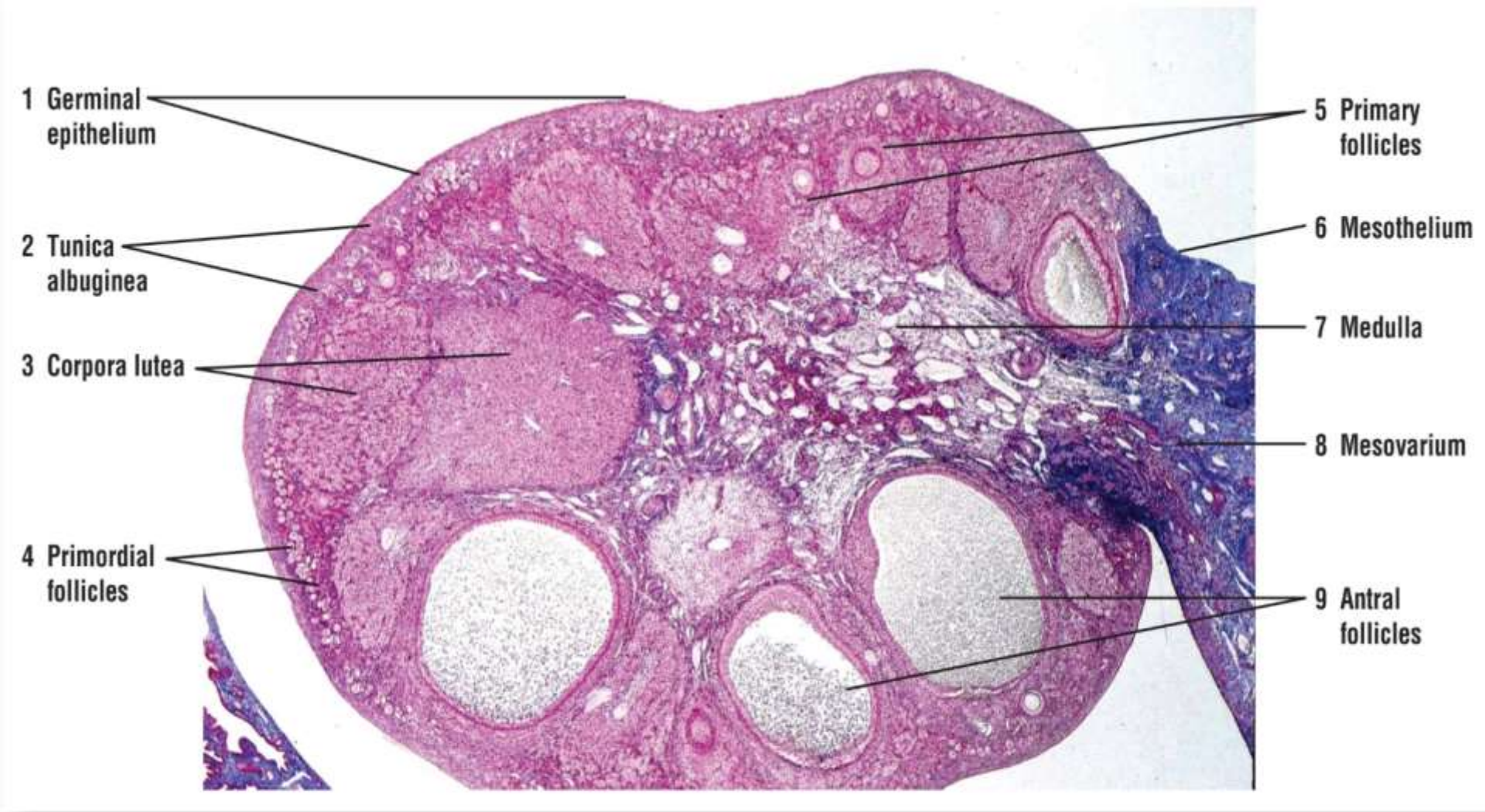

FIGURE 21.2 ■ Ovary: longitudinal section of a feline (cat) ovary showing numerous follicles and corpora lutea. Stain: Mallory-Azan. ×6.5.

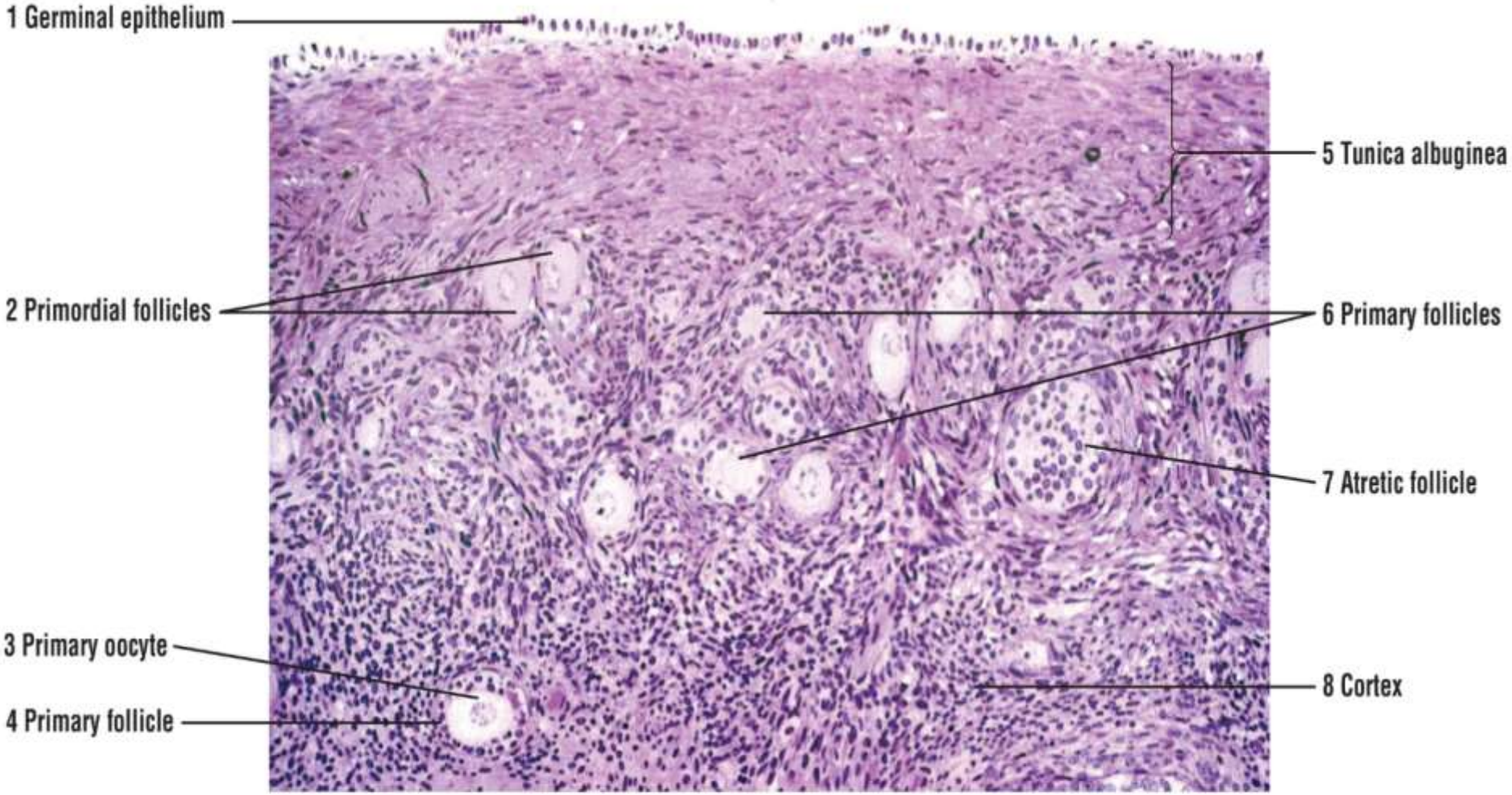

FIGURE 21.3 ■ Ovary: a section of ovarian cortex and developing follicles. Stain: hematoxylin and eosin. ×64.

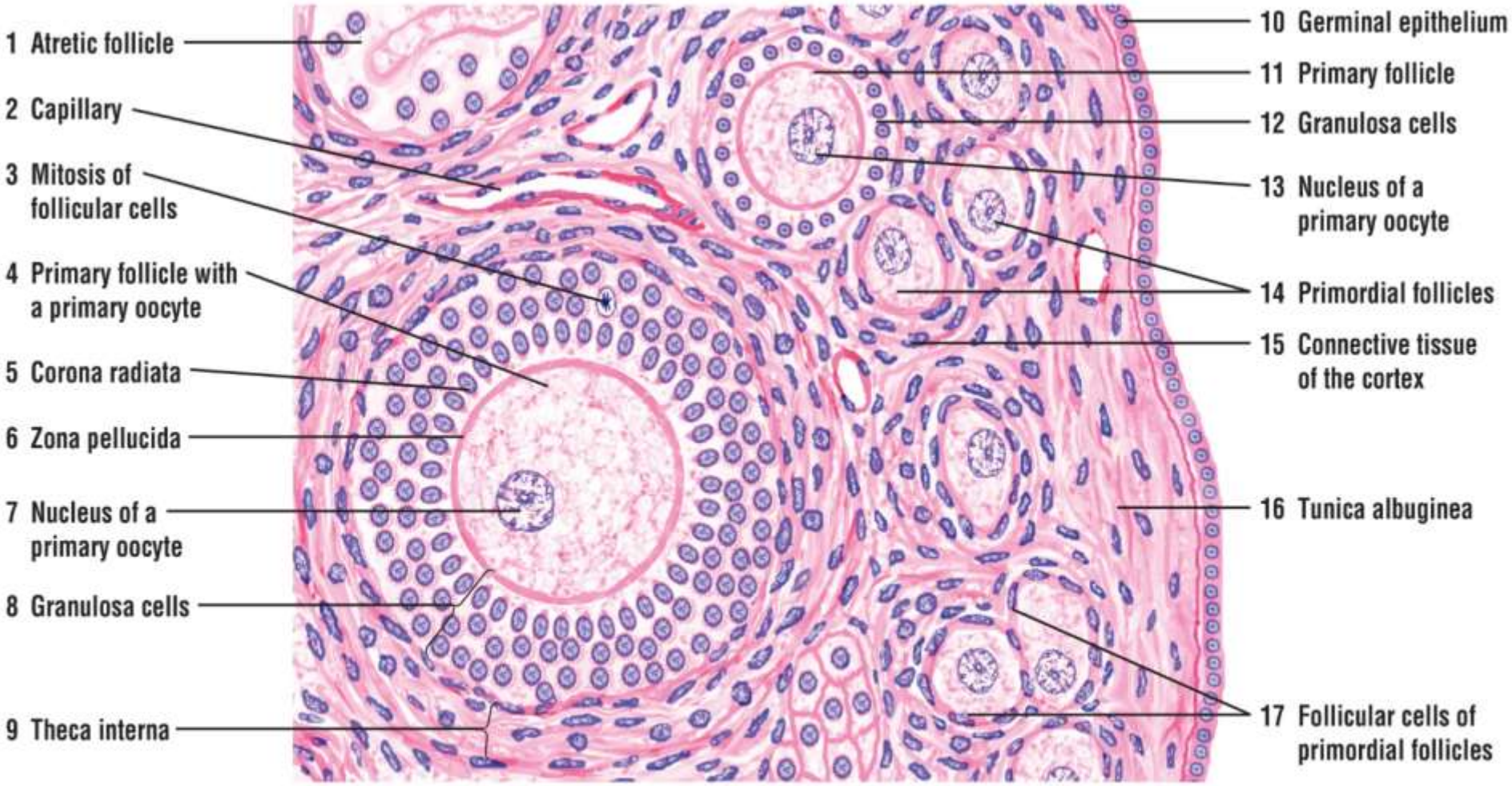

FIGURE 21.4 ■ Ovary: ovarian cortex and primordial and primary follicles. Stain: hematoxylin and eosin. Low magnification.

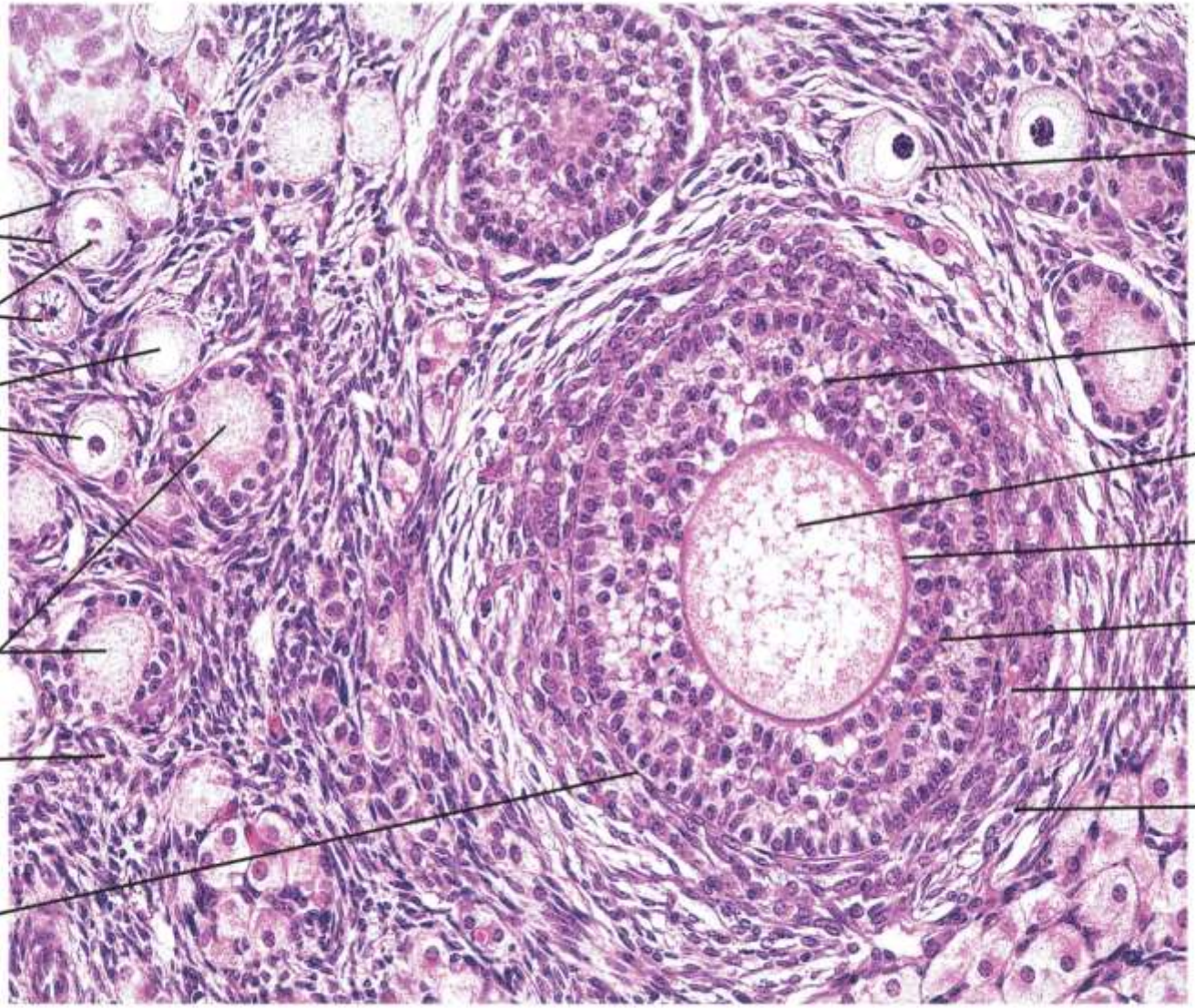

FIGURE 21.5 ■ Ovary: primordial and primary follicles. Stain: hematoxylin and eosin. ×64.

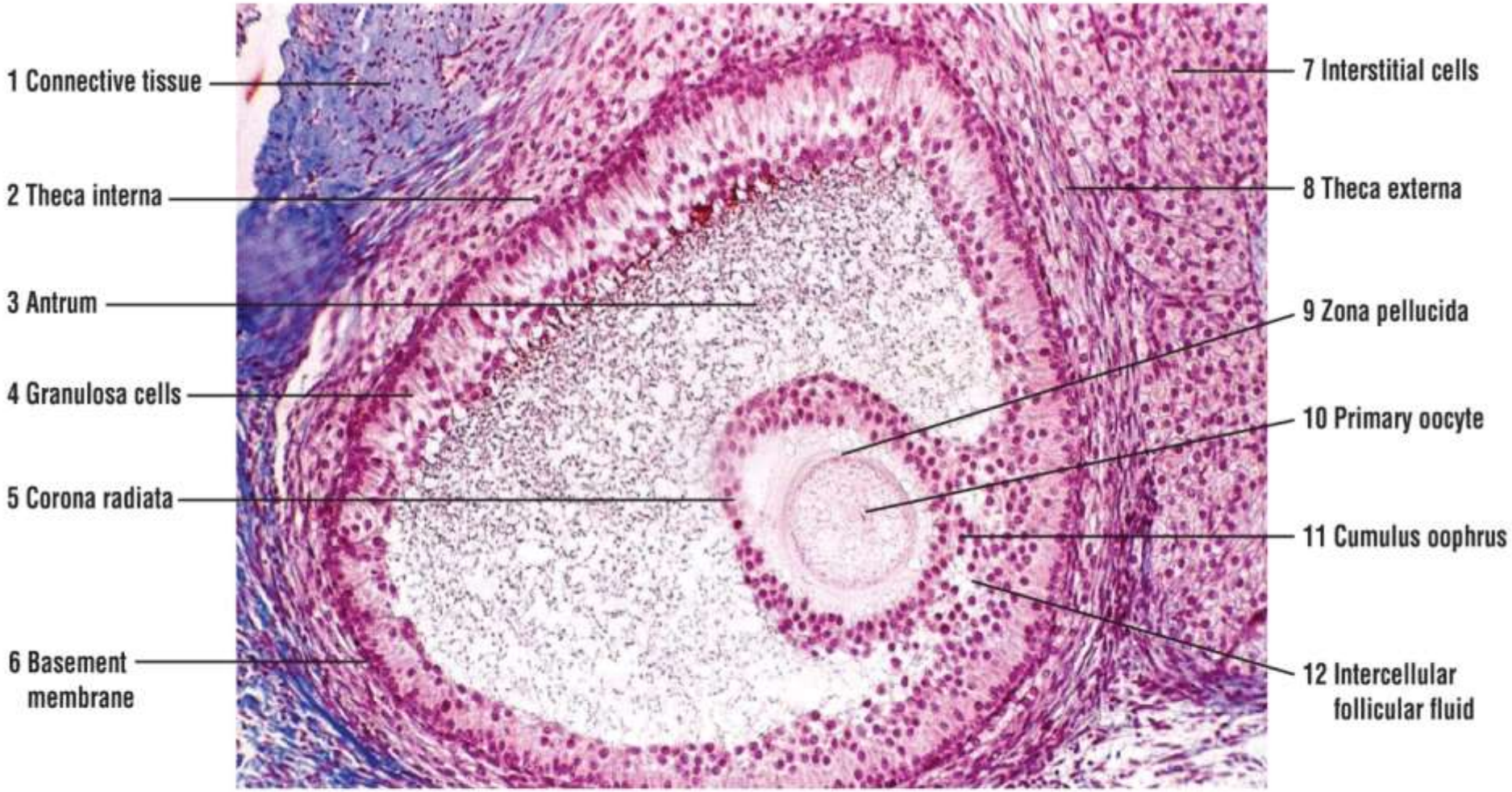

FIGURE 21.6 ■ Ovary: maturing ovarian follicle in feline (cat) ovary. Stain: Mallory-Azan. ×45.

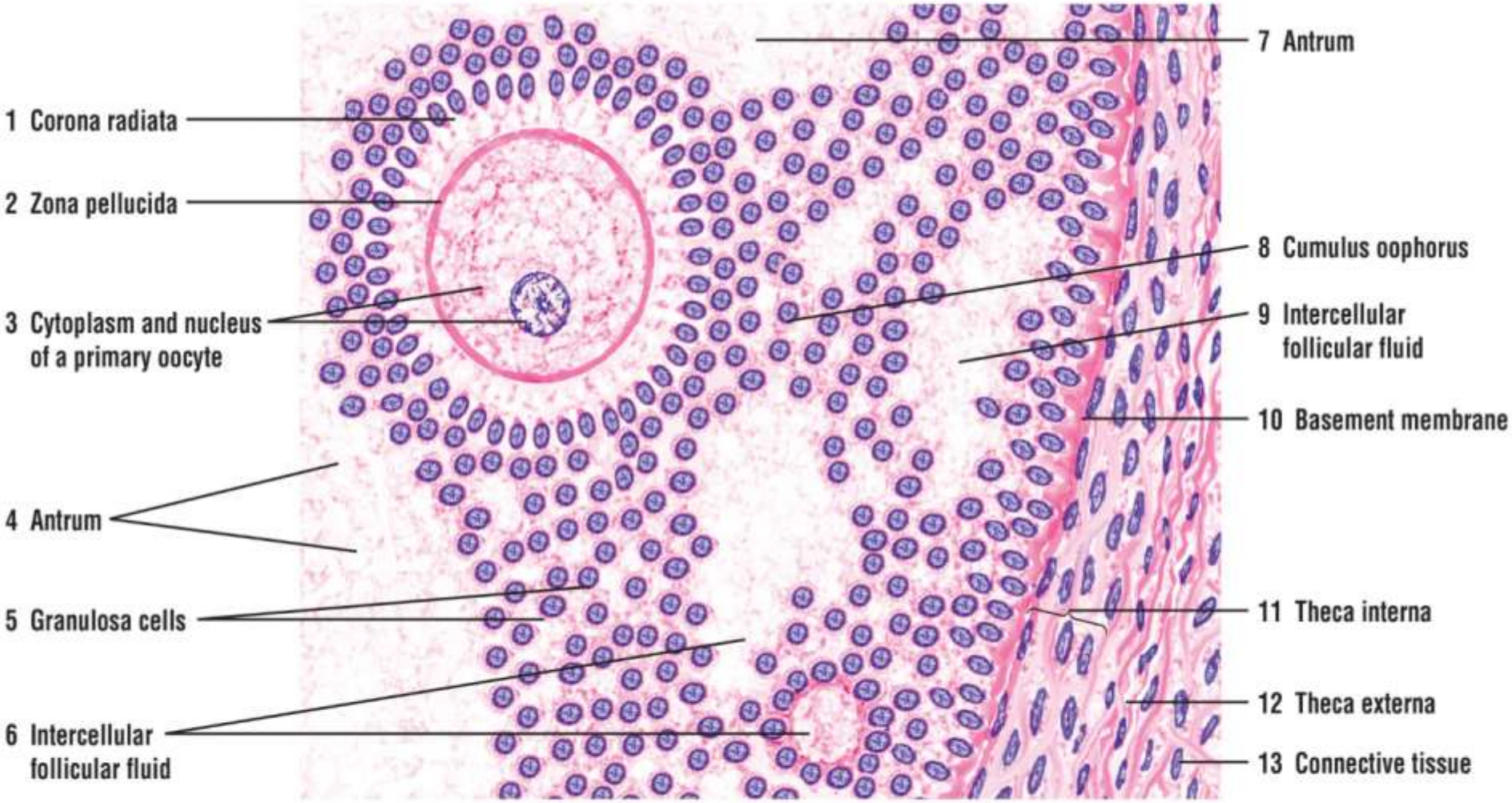

FIGURE 21.7 ■ Ovary: primary oocyte and wall of a mature follicle. Stain: hematoxylin and eosin. High magnification.

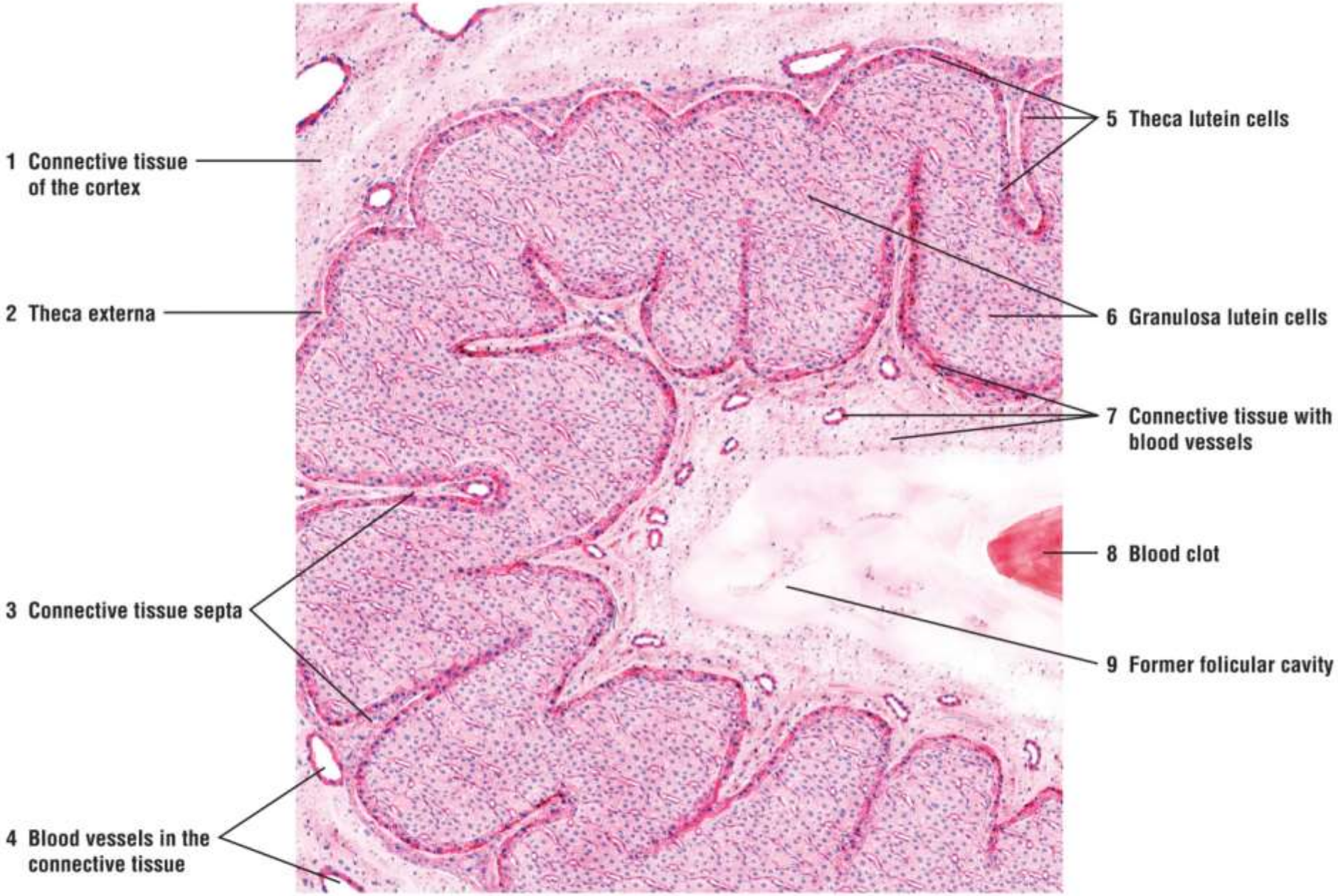

FIGURE 21.8 ■ Corpus luteum (panoramic view). Stain: hematoxylin and eosin. Low magnification.

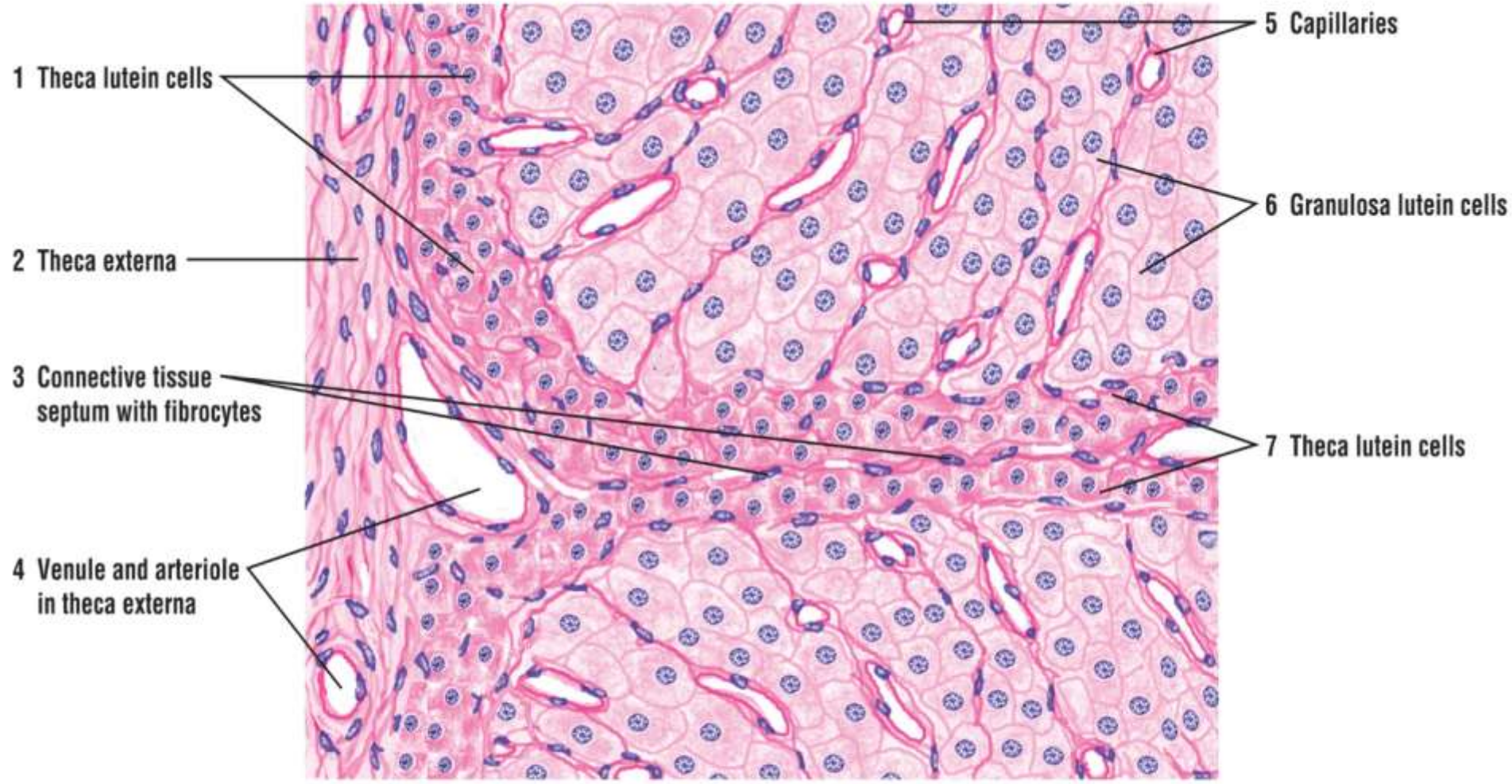

FIGURE 21.9 ■ Corpus luteum: theca lutein cells and granulosa lutein cells. Stain: hematoxylin and eosin.

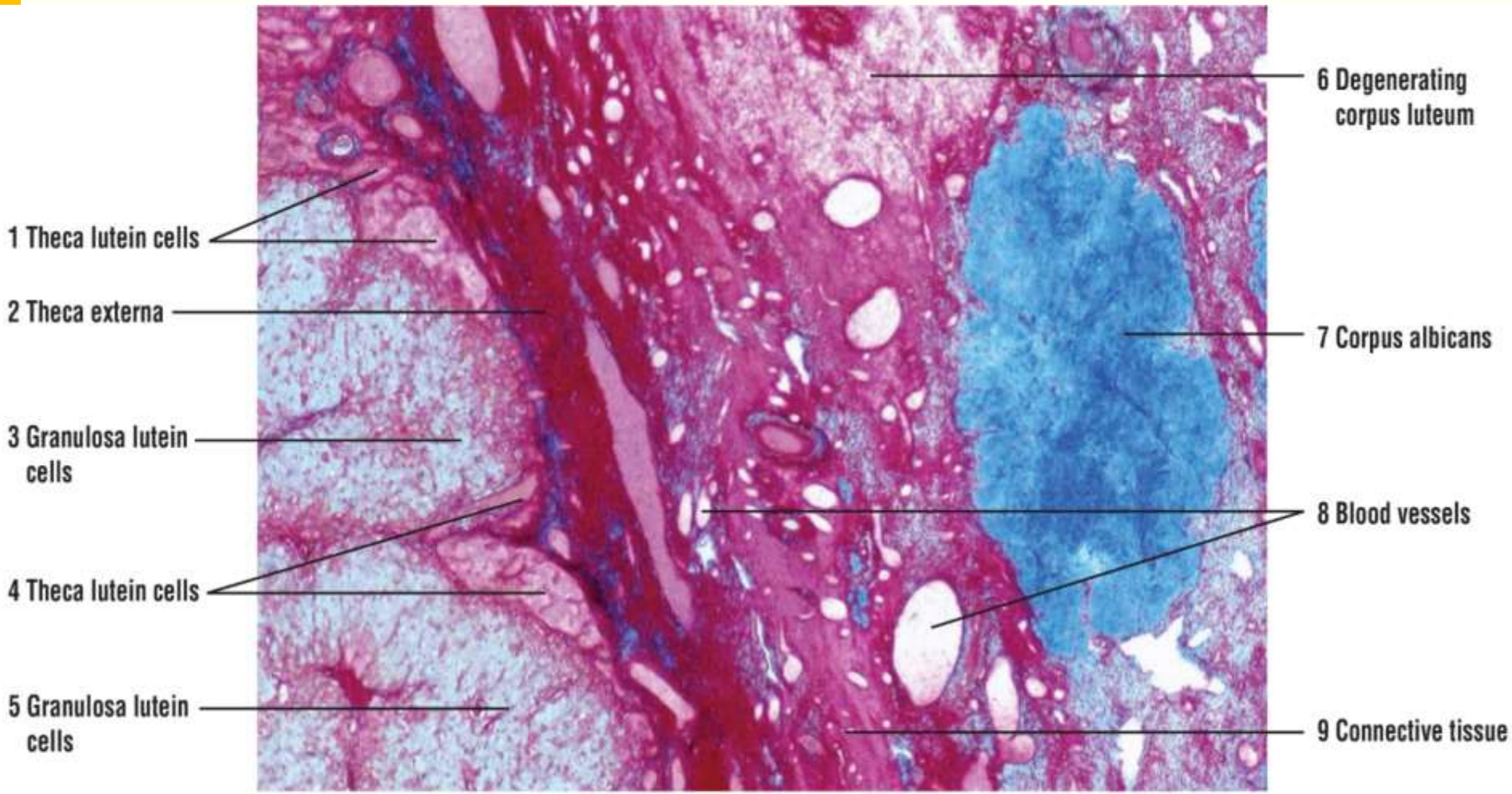

FIGURE 21.10 ■ Human ovary: a section of corpus luteum and corpus albicans. Stain: Mallory-Azan. ×10.5.

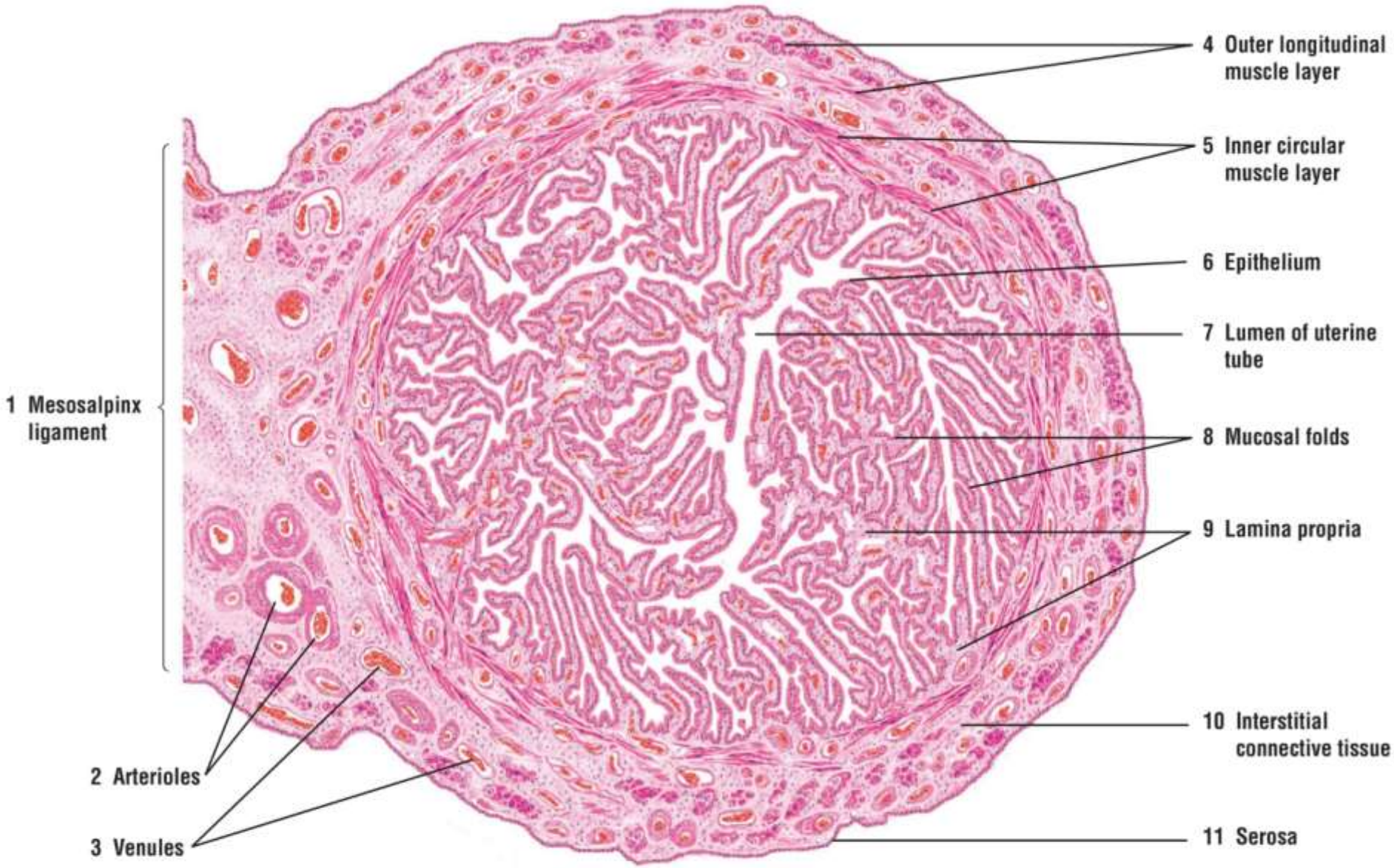

FIGURE 21.11 ■ Uterine tube: ampulla with mesosalpinx ligament (panoramic view, transverse section). Stain: hematoxylin and eosin. Low magnification.

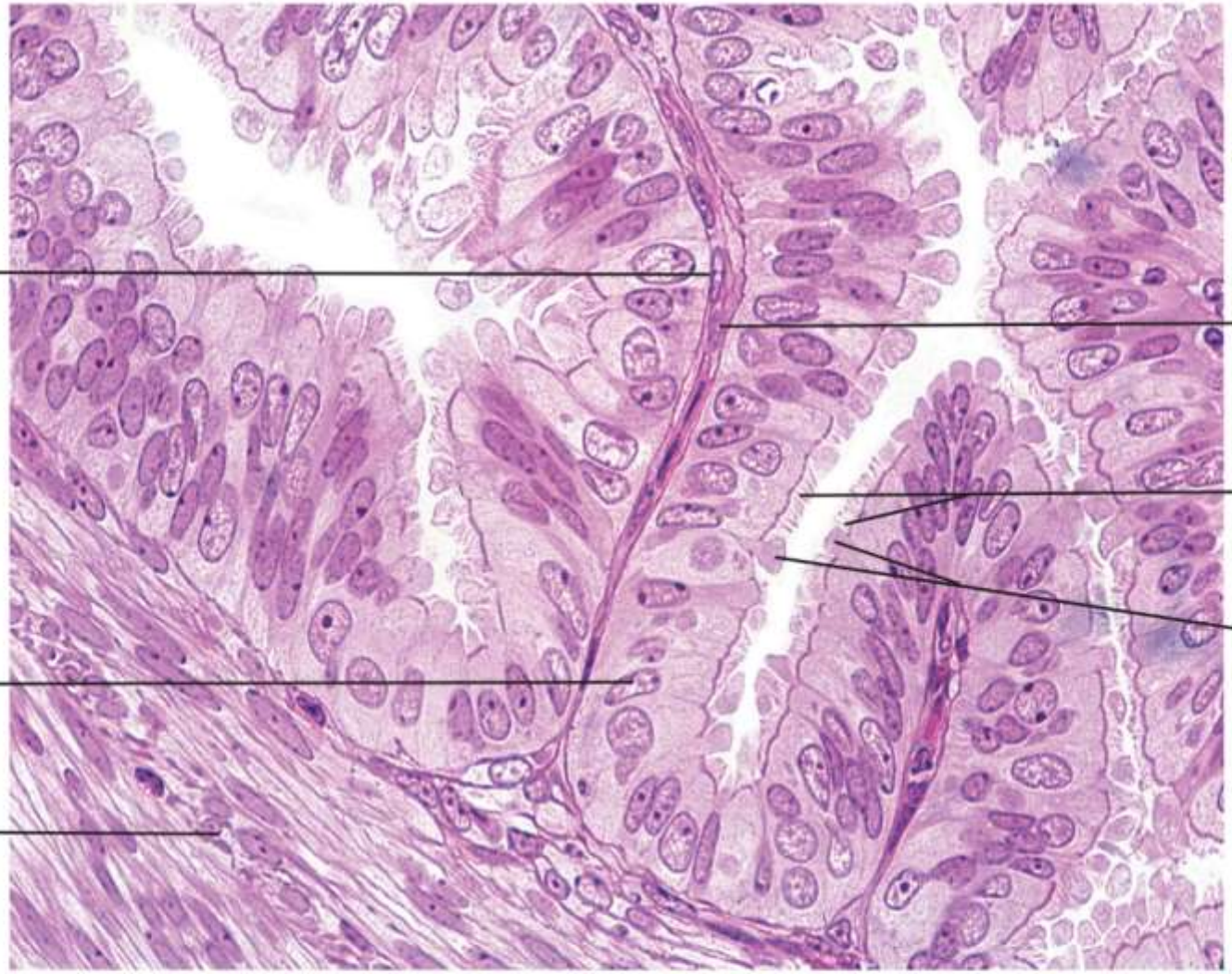

FIGURE 21.13 ■ Uterine tube: lining epithelium. Stain: hematoxylin and eosin (plastic section). ×130.

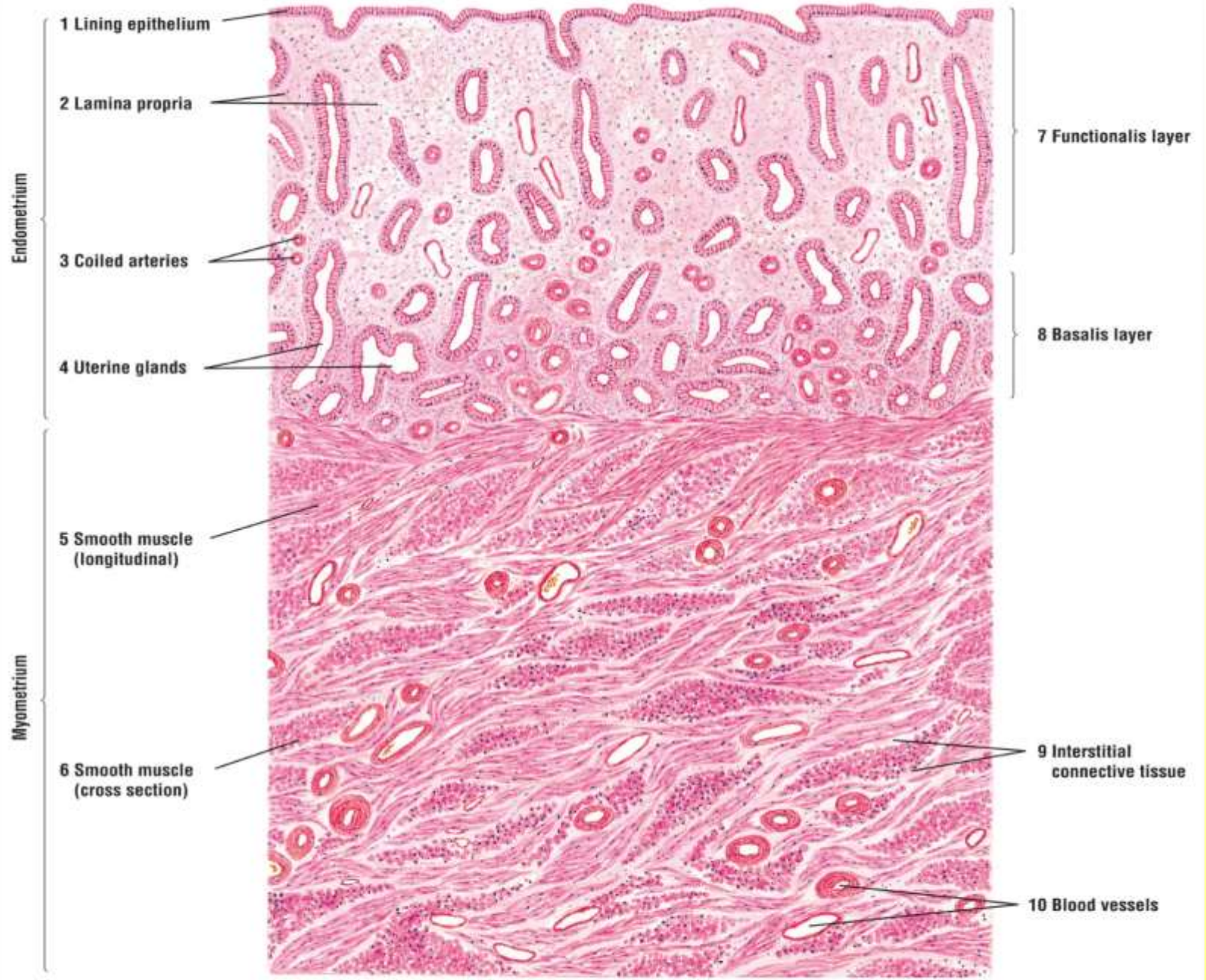

FIGURE 21.14 ■ Uterus: proliferative (follicular) phase. Stain: hematoxylin and eosin. Low magnification.

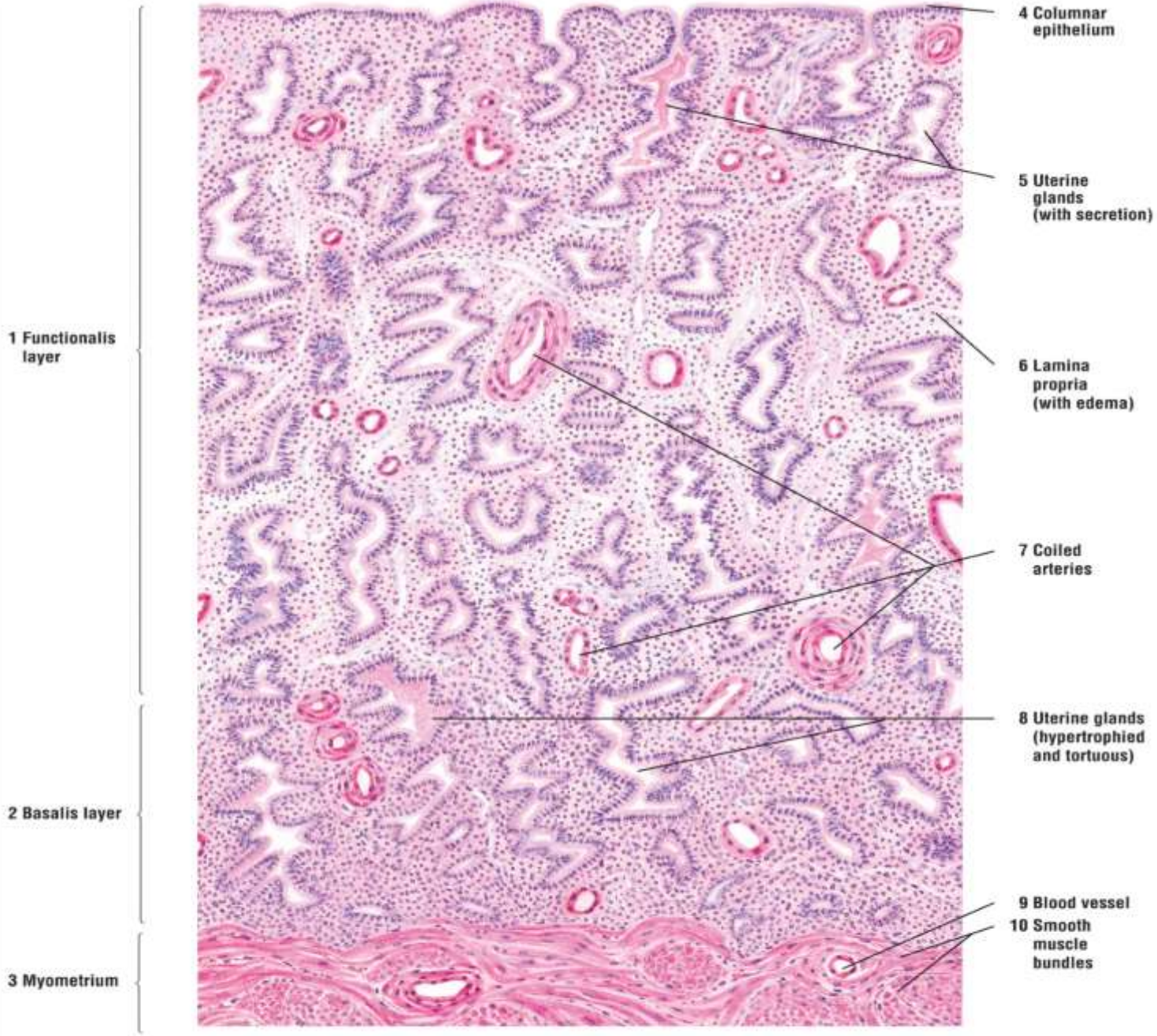

FIGURE 21.15 ■ Uterus: secretory (luteal) phase. Stain: hematoxylin and eosin. Low magnification.

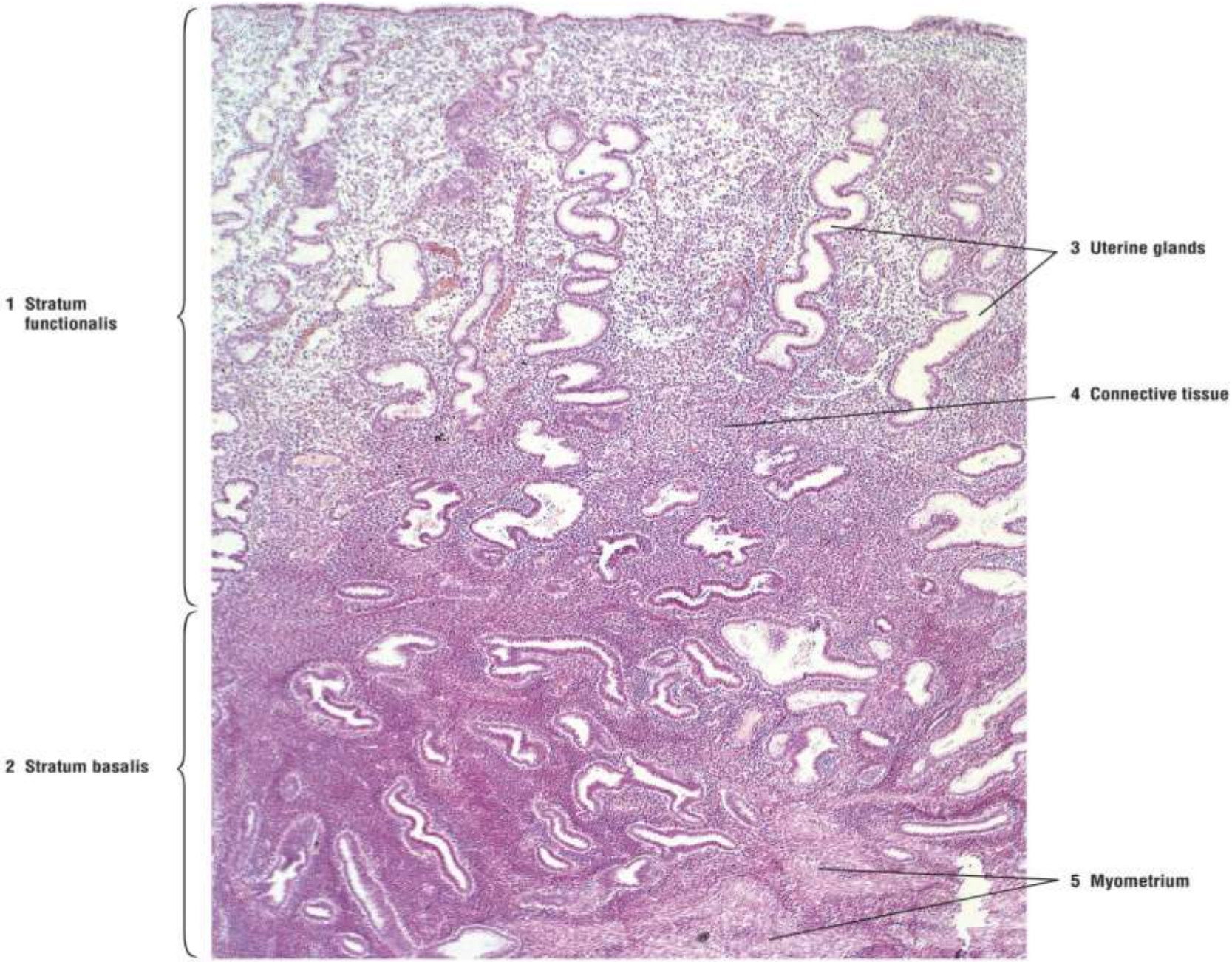

FIGURE 21.16 ■ Uterine wall (endometrium): secretory (luteal) phase. Stain: hematoxylin and eosin. ×10.

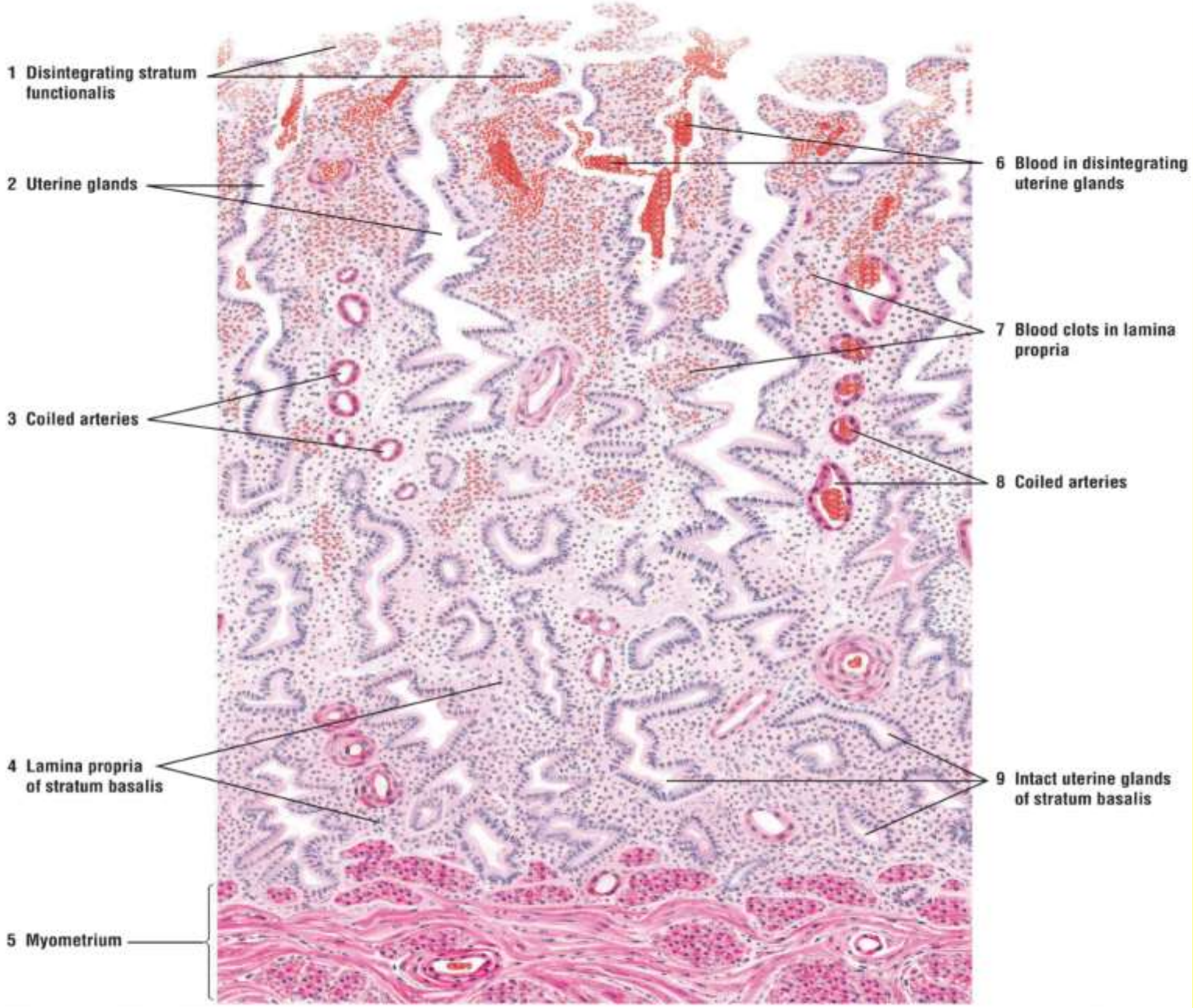

FIGURE 21.17 ■ Uterine wall: menstrual phase. Stain: hematoxylin and eosin. Low magnification.

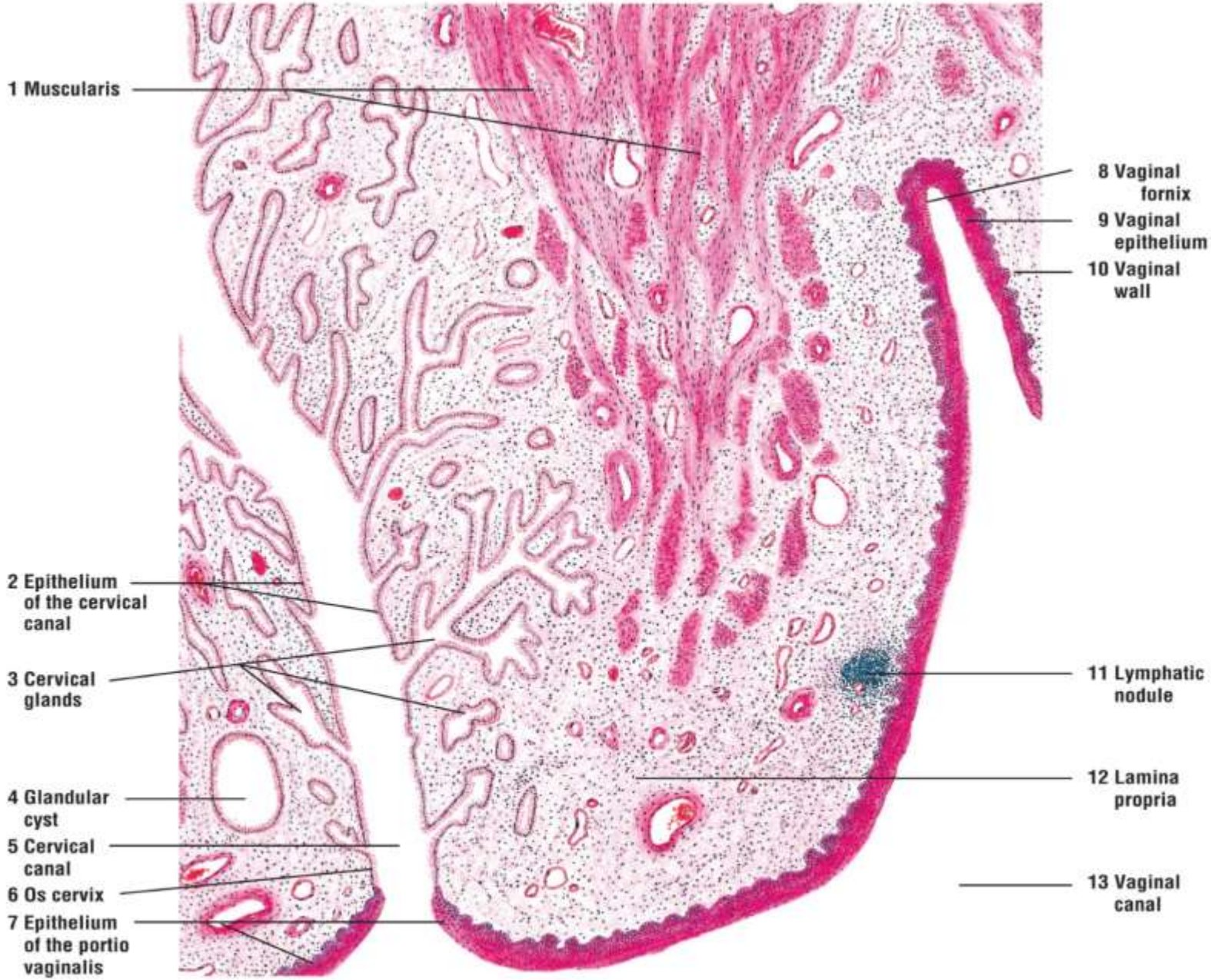

FIGURE 21.18 ■ Cervix, cervical canal, and vaginal fornix (longitudinal section). Stain: hematoxylin and eosin. Low magnification.

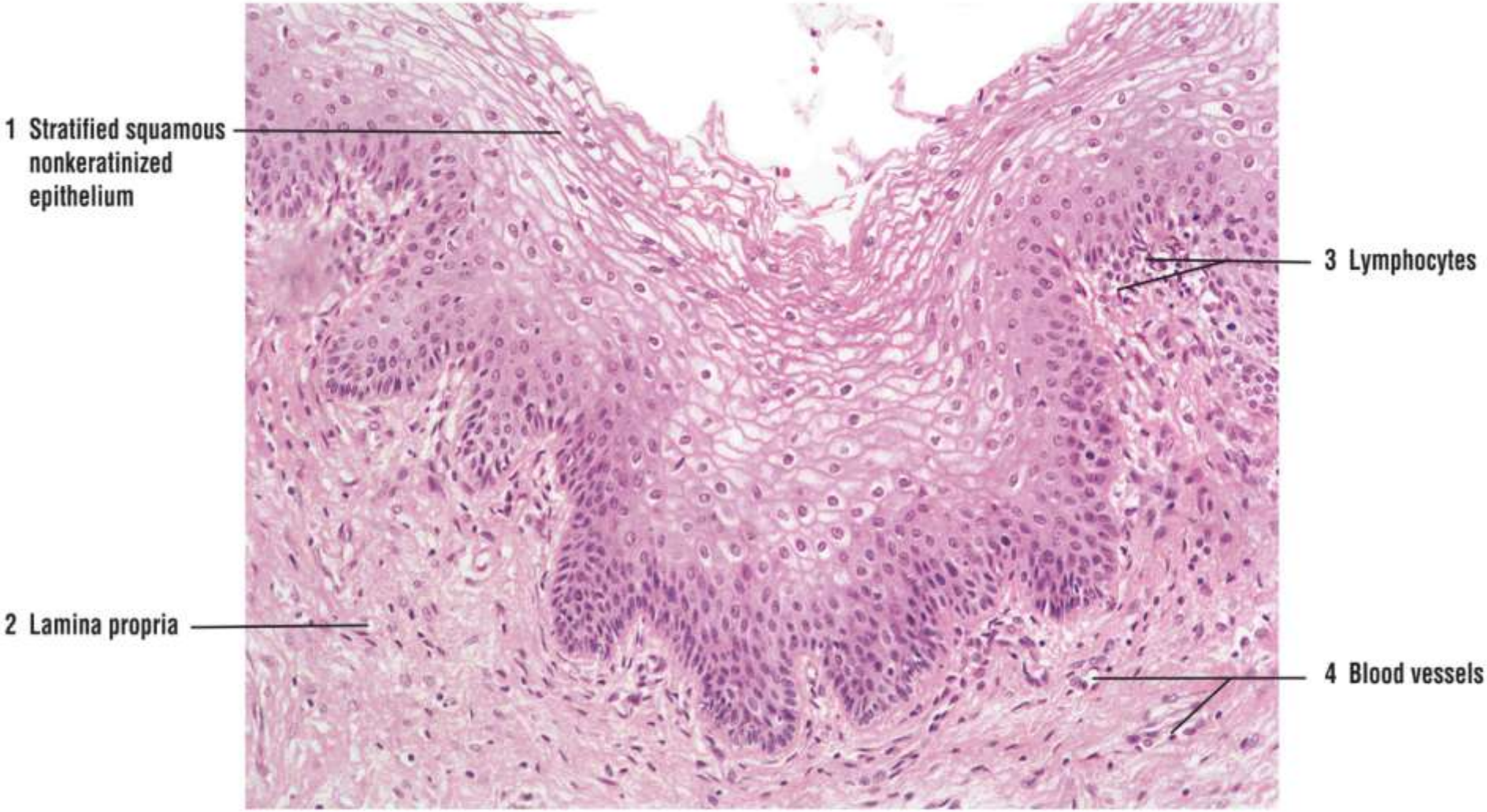

FIGURE 21.22 ■ Vagina: surface epithelium. Stain: hematoxylin and eosin. ×50.

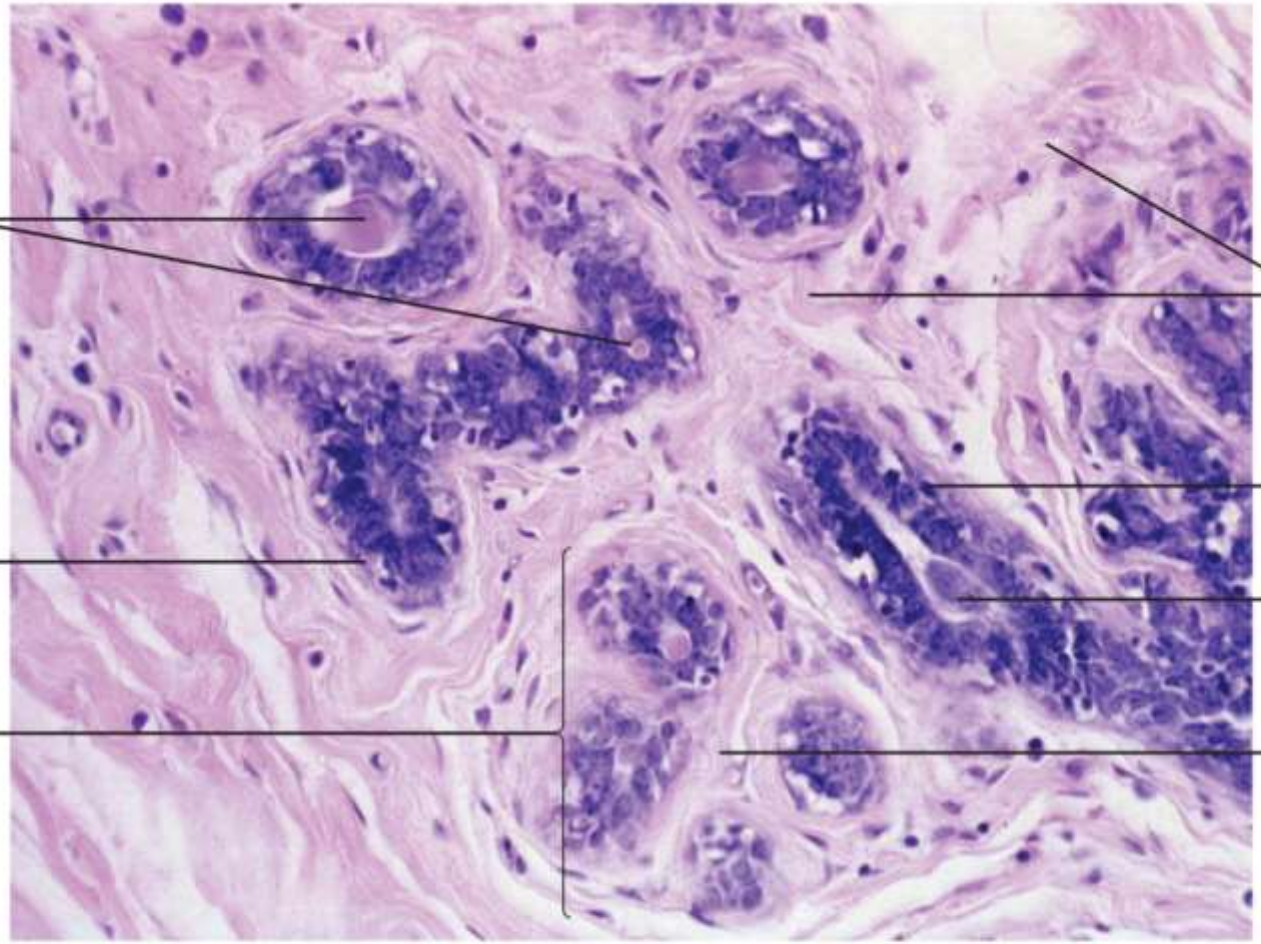

FIGURE 21.27 ■ Mammary gland: micrograph of inactive mammary gland. Stain: hematoxylin and eosin. ×102.

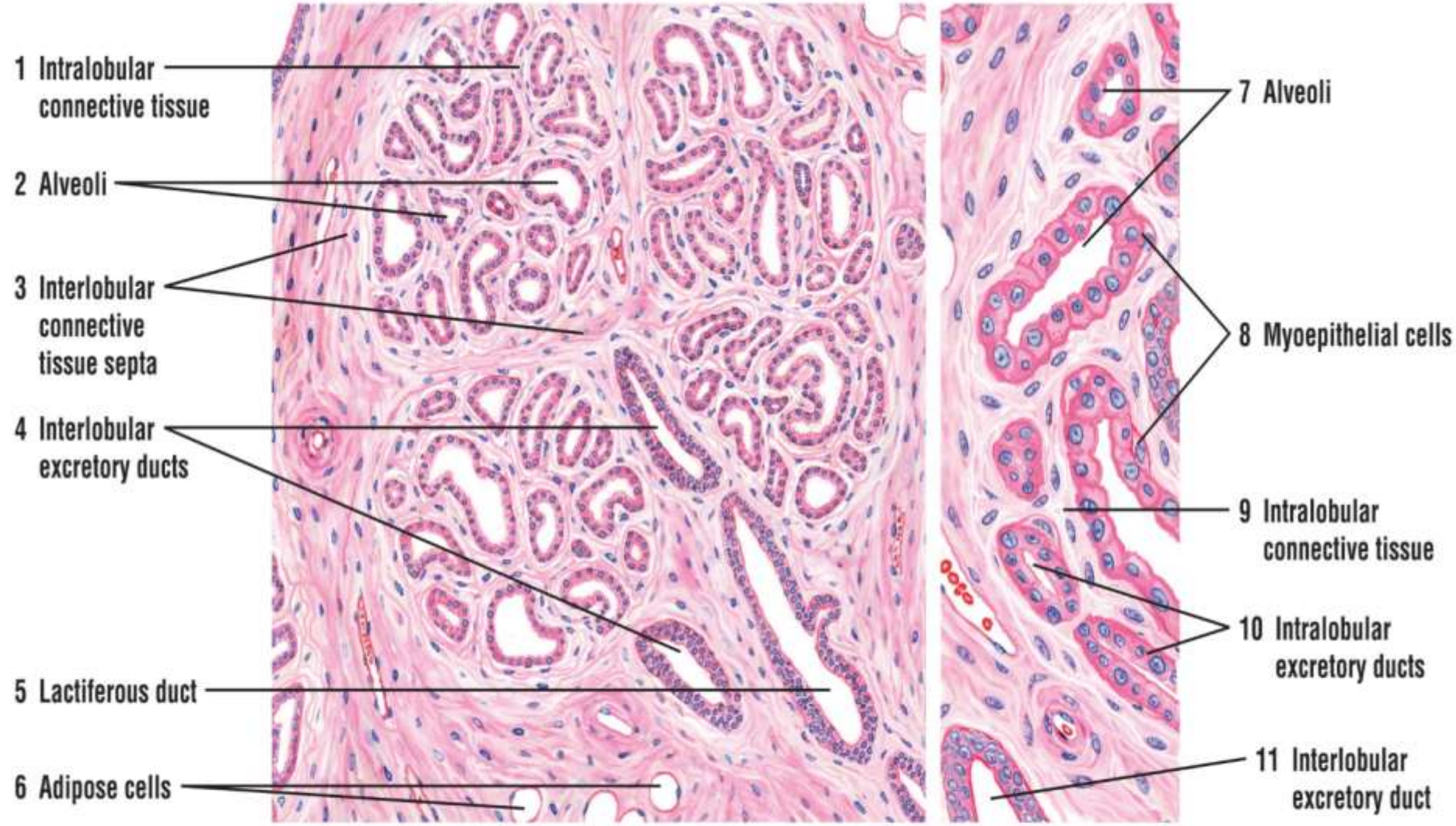

FIGURE 21.28 ■ Mammary gland during proliferation and early pregnancy. Stain: hematoxylin and eosin. Left side, medium magnification; right side, high magnification.

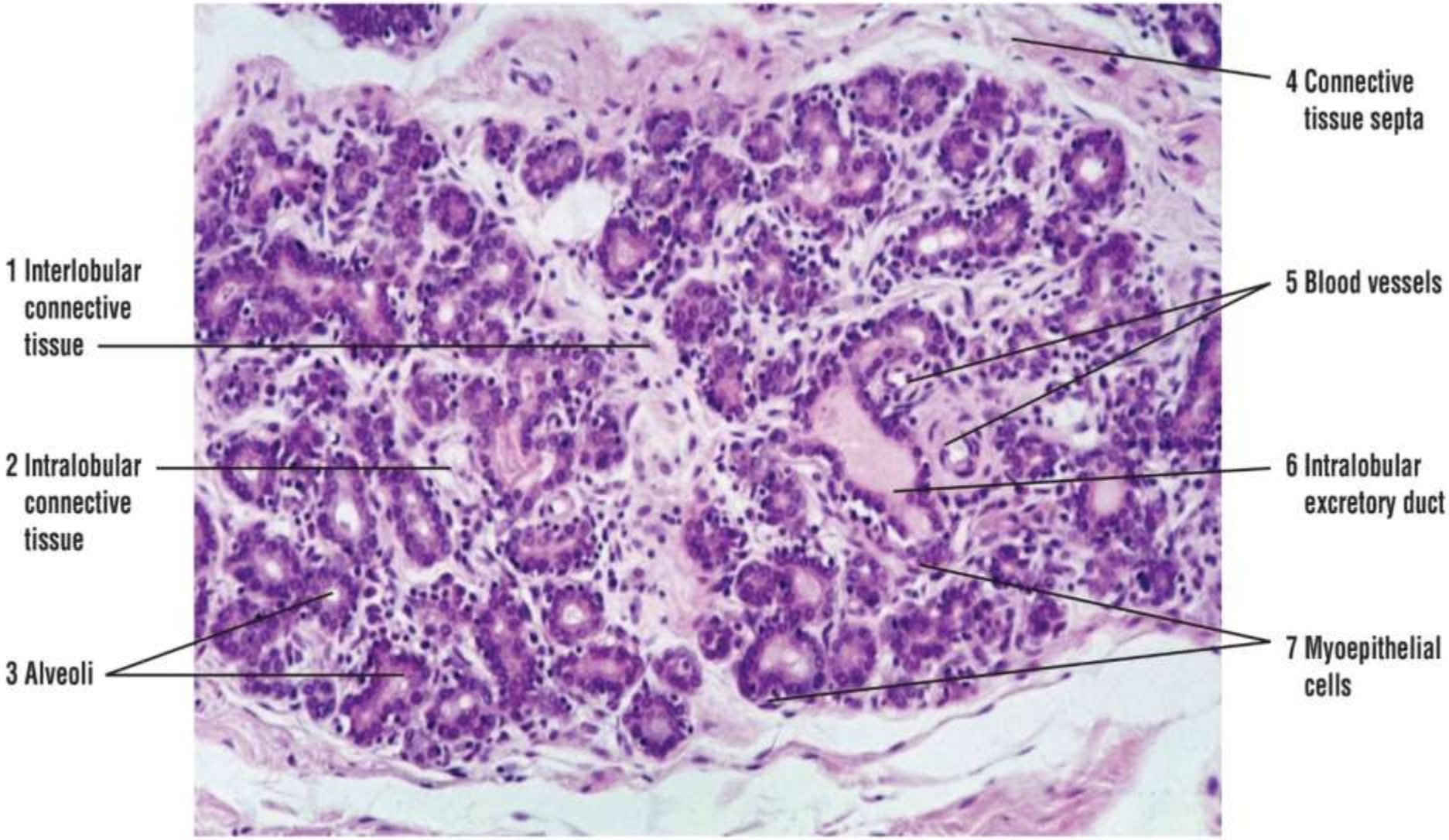

FIGURE 21.29 ■ Mammary gland during activation and early development. Stain: hematoxylin and eosin. ×85.

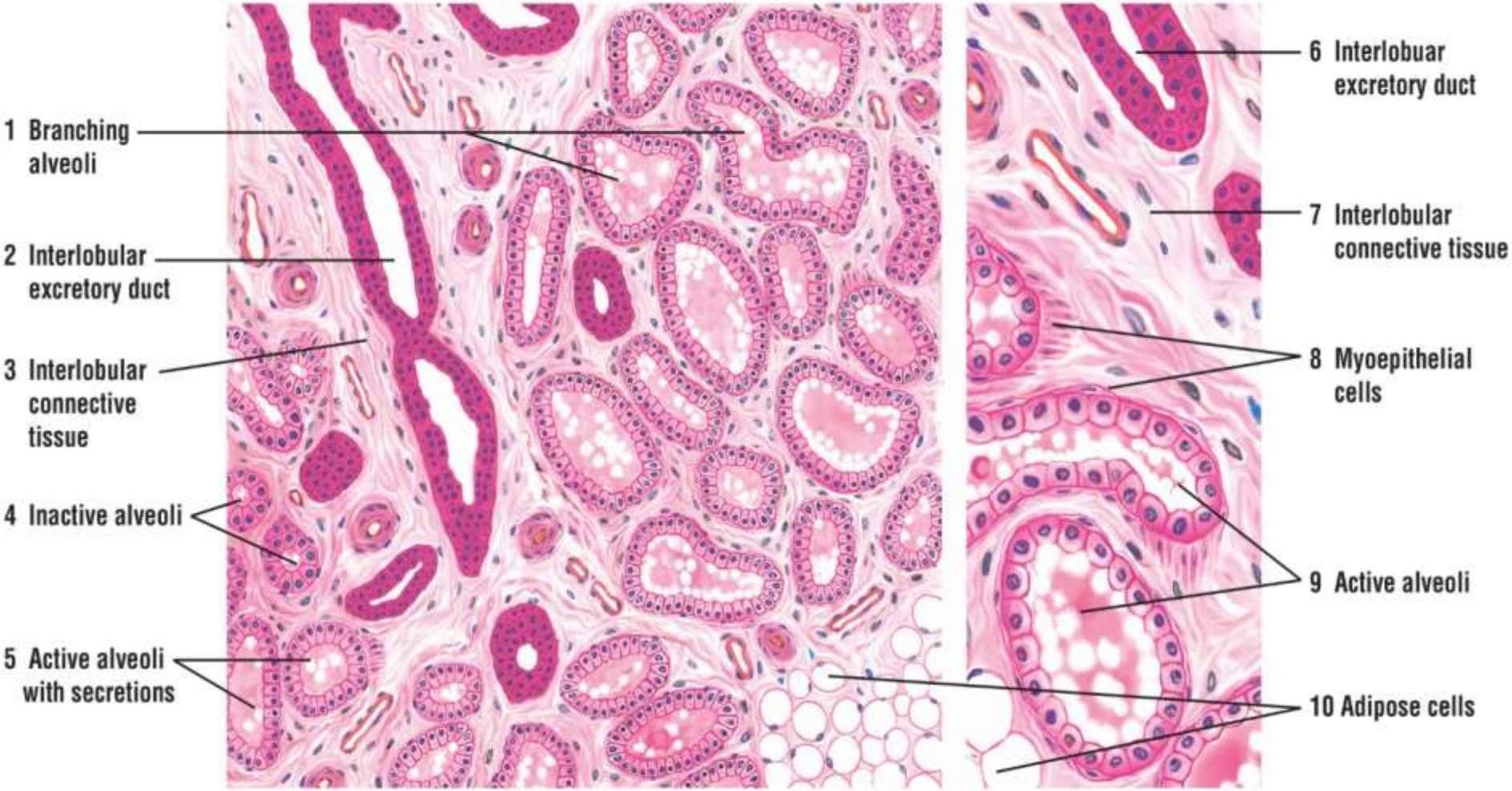

FIGURE 21.31 ■ Mammary gland during lactation. Stain: hematoxylin and eosin. Left side, medium magnification; right side, high magnification.

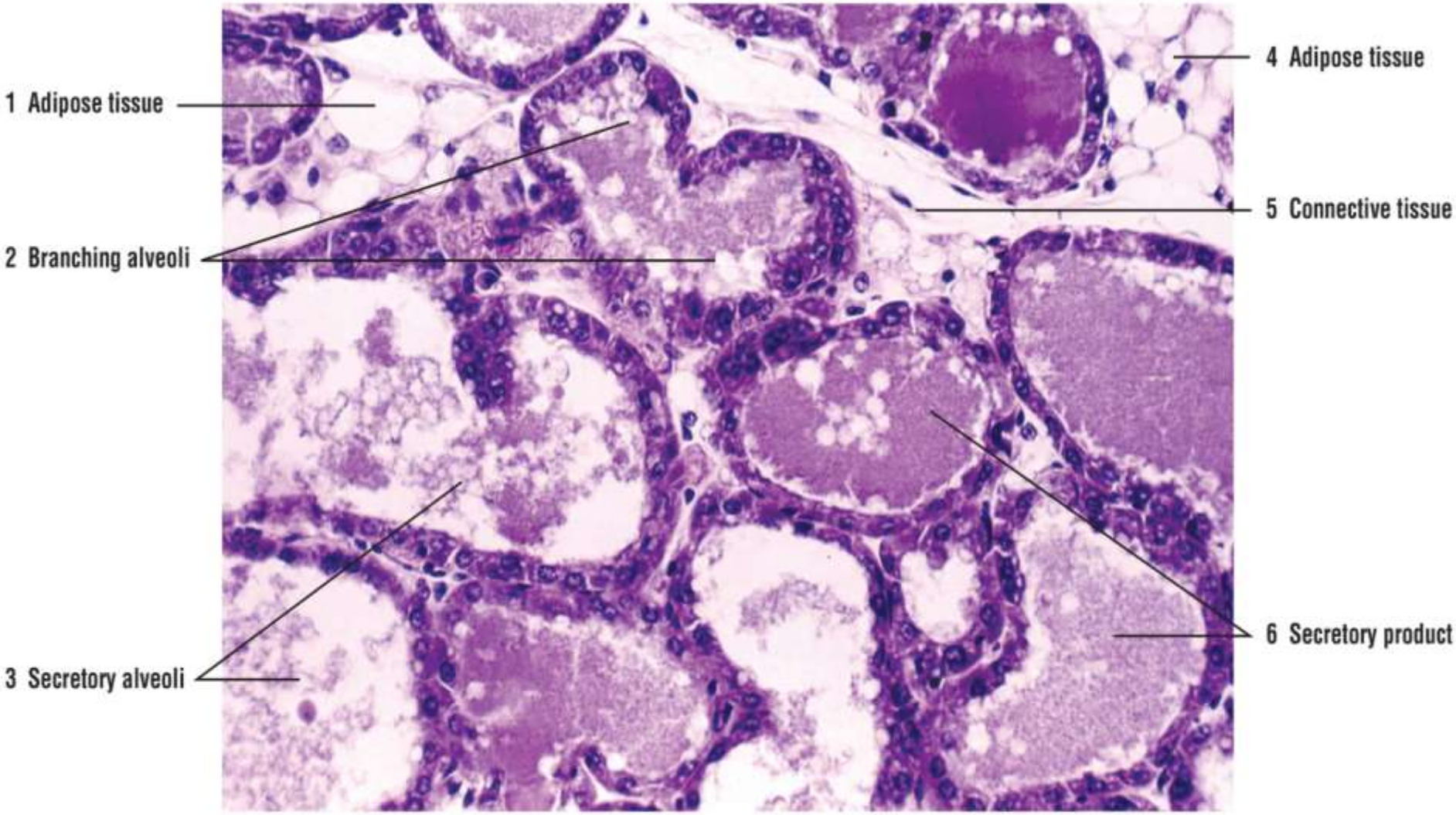

FIGURE 21.32 ■ Lactating mammary gland. Stain: hematoxylin and eosin. ×75.