DIPHYLLOBOTHRIUM LATUM

(FISH OR BROAD TAPEWORM)

Epidemiology

Fish tapeworm infection is distributed worldwide, in the temperate regions; it is associated with eating of raw or improperly cooked fresh water fish

- **Morphology**

  This is the longest tapeworm found in man, ranging from 3-10 meters with more than 3000 proglottids. The scolex resembles two almond-shaped leaves and the proglottids are broader than they are long, a morphology reflected in the organism's name. Eggs are 30 x 50 micrometers in size and contain an embryo with 3 pairs of hooklets

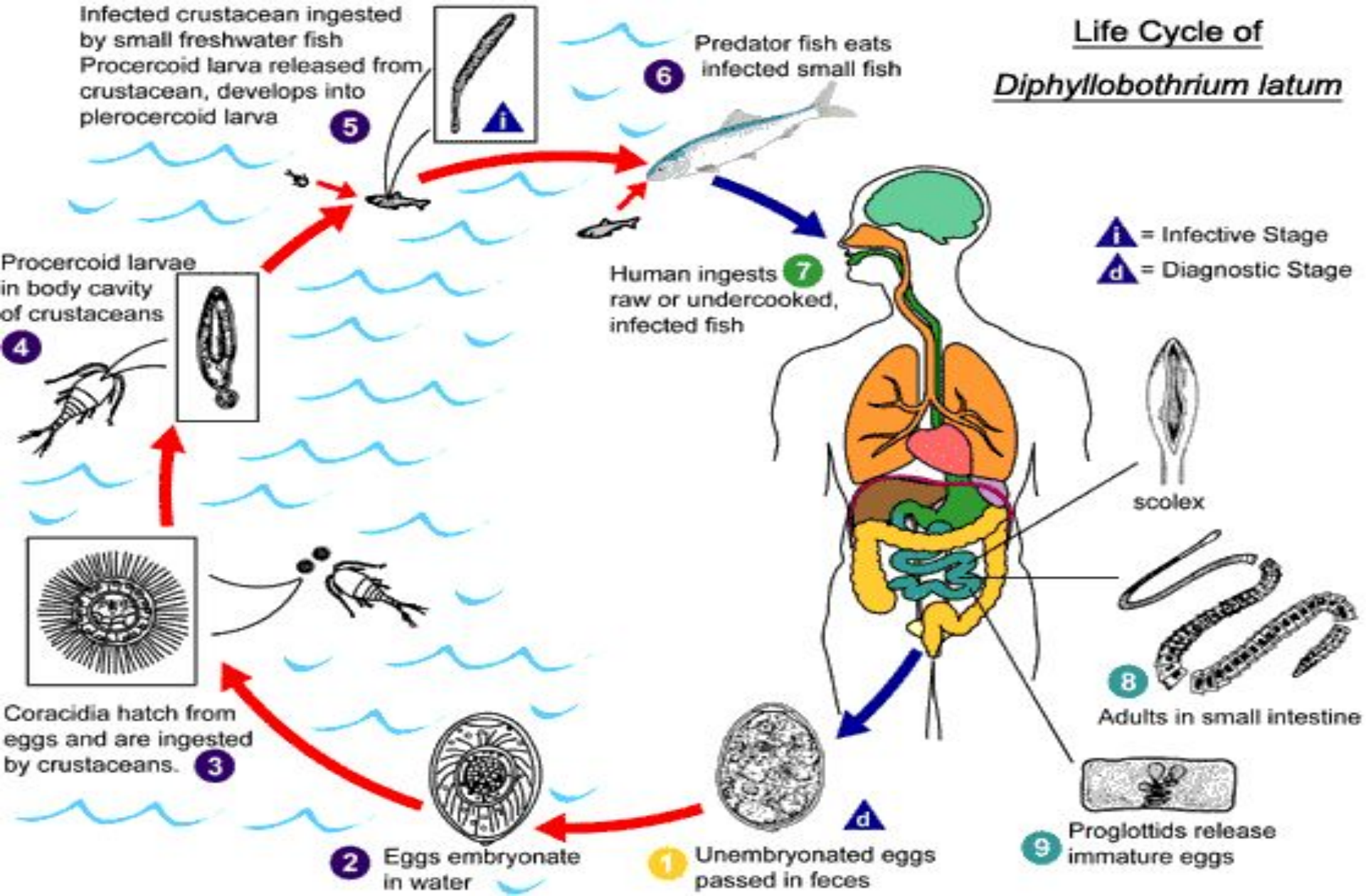
Life Cycle of
Diphyllobothrium latum
Infected crustacean ingested by small freshwater fish Procercoid larva released from crustacean, develops into plerocercoid larva
5
Predator fish eats infected small fish
6
Procercoid larvae in body cavity of crustaceans
4
Human ingests raw or undercooked, infected fish
7
i = Infective Stage
d = Diagnostic Stage
scolex
8
Adults in small intestine
Coracidia hatch from eggs and are ingested by crustaceans.
3
2
Eggs embryonate in water
1
Unembryonated eggs passed in feces
9
Proglottids release immature eggs

Life cycle .

.the gravid segments are retained by the worm-

Operculated eggs passed in feces hatch into small ciliated coracidium- .larvae which swim about freely

These are eaten by crustaceans -Cyclops or Diaptomus -

.in which the larvae develop into second stage larvae- the procercoid -

When the crustaceans are swallowed by fresh water fish, the larvae - migrate into the flesh of the muscle fish and develop to pleurocercoid or .sparganum larvae

.Humans are infected by ingesting raw or improperly cooked fish -

The tapeworm matures in the intestine and after 3 weeks, the adult- .worm discharges eggs. The life cycle requires two intermediate hosts

Symptoms

Clinical symptoms may be mild, depending on the number of worms. They include abdominal discomfort, loss of weight, loss of appetite and some malnutrition. Anemia and neurological problems associated with vitamin B12 deficiency are seen in heavily infected individuals

Diagnosis

Diagnosis is based on finding many typical eggs and empty proglottids in feces. A history of raw fish consumption and residence in an endemic locality is helpful.

Treatment and control

Praziquantel is the drug of choice. Freezing for 24 hours, thorough cooking or pickling of fish kills the larvae. Fish reservoirs should be kept free of raw sewage.
.Niclosamide: 2 gm PO stat after light breakfast

:Prevention

Prohibiting the disposal of untreated sewage into fresh water /lakes.Personal protection: cooking of all fresh water fish

Ascaris lumbricoides* and *Ascaris suum
(intestinal roundworms of humans and pigs)

Introduction:
Ascaris lumbricoides is one of the largest and most common nematones found in humans. The adult females of this species can measure up to 18 inches long (males are generally shorter), and it is estimated that 25% of the world's population is infected with .this nematode

- **Life cycle:**
- -The adult worms live in the small intestine and eggs are passed in the feces. A single female can produce up to 200,000 eggs each day! About two weeks after passage in the feces
- - the eggs contain an infective larval or juvenile stage, and humans are infected when they ingest such infective eggs. The eggs hatch in the small intestine, the juvenile penetrates the small intestine and enters the circulatory system, and eventually the juvenile worm enters the lungs.
- - In the lungs the juvenile worm leaves the circulatory system and enters the air passages of the lungs. The juvenile worm then migrates up the air passages into the pharynx where it is swallowed, and once in the small intestine the juvenile grows into an adult worm. **Why *Ascaris* undergoes such a migration through the body to only end up where it started is unknown.** Such a migration is not unique to *Ascaris*, as its close relatives undergo a similar migration in the bodies of their hosts

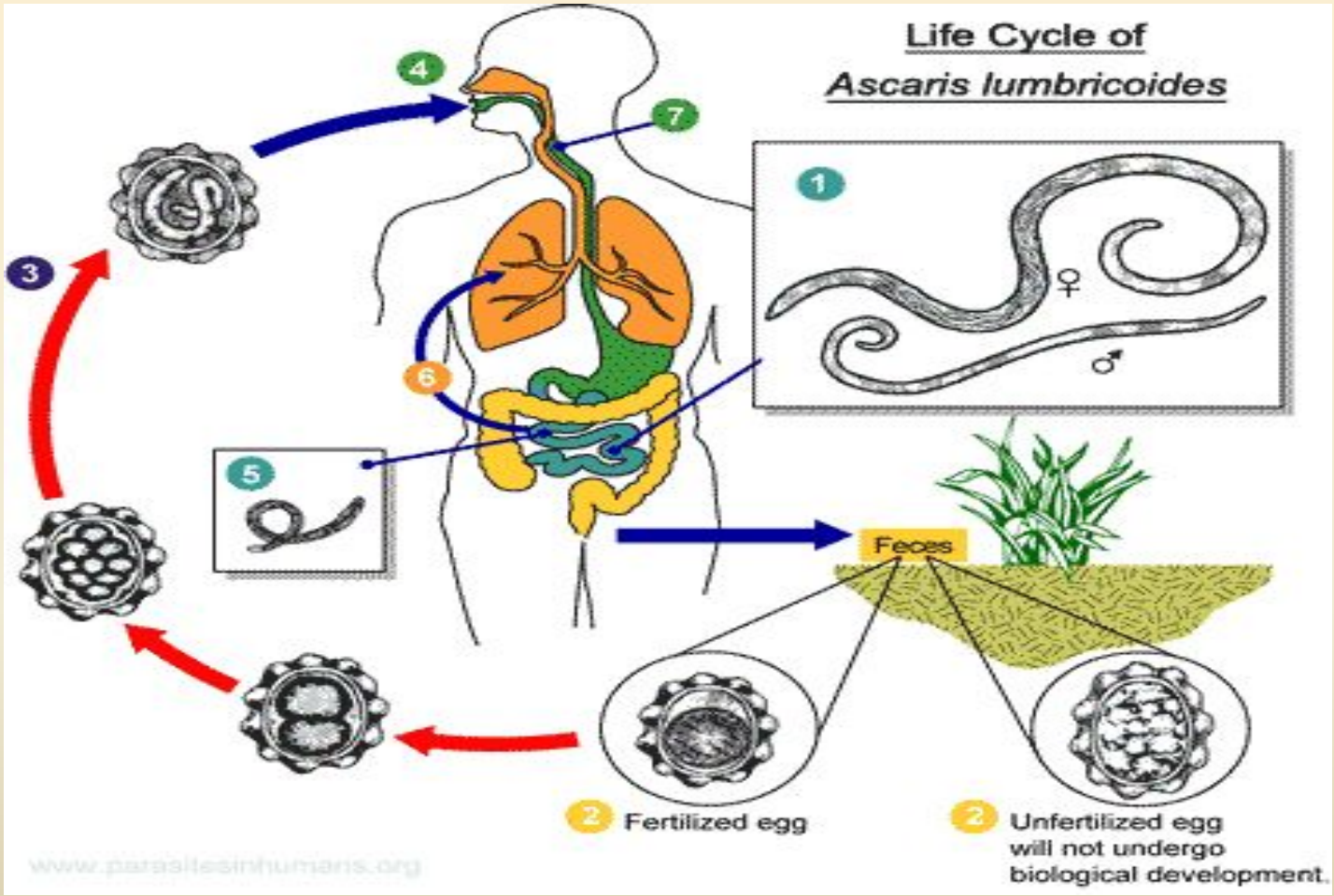
Life Cycle of
Ascaris lumbricoides
1
2 Fertilized egg
2 Unfertilized egg will not undergo biological development.
3
4
5
6
7
Feces
www.parasitesinhumans.org

:Pathology and clinical signs

larval stage

Ascaris infections in humans can cause significant pathology. The migration of the larvae through the lungs causes the blood vessels of the lungs to hemorrhage, and there is an inflammatory response accompanied by edema. The resulting accumulation of fluids in the lungs results in ."ascaris pneumonia," and this can be fatal

adult stage

The large size of the adult worms also presents problems, especially if the .worms physically block the gastrointestinal tract

extraintestainal ascariasis

Ascaris is infamous for its character to migrate within the small intestine, and when a large worm begins to migrate there is not much that can stop it. Cases have been reported in which *Ascaris* have migrated into and blocked the bile or pancreatic duct or in which the worms have penetrated the small intestine resulting in acute (and fatal) peritonitis. *Ascaris* seems to be especially sensitive to anesthetics, and numerous cases have been documented where patients in surgical recovery rooms have had worms migrate from the small intestine, through the stomach, and out the patient's .nose or mouth

Treatment

Treatment includes medications that paralyze or kill intestinal parasitic worms, such as albendazole or mebendazole. These drugs should not be used for pregnant patients. Pyrantel pamoate is the preferred medication .for pregnant patients

If there is a blockage of the intestine caused by a large number of worms, .endoscopy to remove the worms or, rarely, surgery may be needed

Ascaris suum

Ascaris suum is found in pigs. Its life cycle is identical to that of *A. lumbricoides*. If a human ingests eggs of *A. suum* the larvae will migrate to the lungs and die. This can cause a particularly serious form of "ascaris pneumonia." Adult worms of this species do not develop in the human's .intestine

Diagnosis

Infections of *Ascaris* are diagnosed by finding .characteristic eggs in the feces of the infected host

- Scolex: *D. latum* has a typical Pseudophyllidean scolex possessing two bothria or sucking gooves. These are longitudinal grooves used in attachment to the intestinal wall

- Mature Proglottid: The genital and uterine pores open to the ventral surface in the center of the proglottid (black arrow, compare to lateral pores in other species). There are numerous testes throughout and a bilobed ovary posteriorly (red arrow). In gravid proglottids, the uterus has a characteristic rosette shape

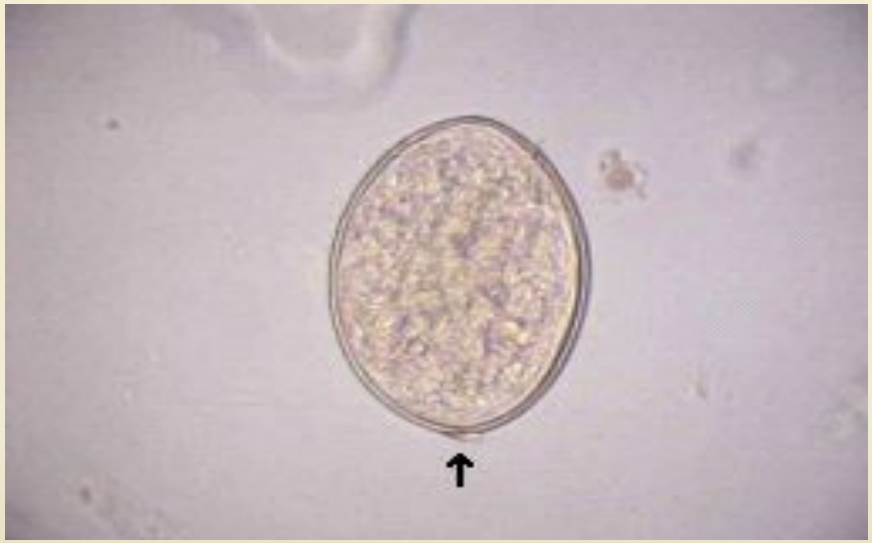

- Egg: The eggs are undeveloped when passed - approximately 40 x 60 um with an operculum (not clear in this photo). There is a small knub on the abopercular end (arrow(

- Plerocercoid: This stage is found in the fish, second intermediate hosts as is the infective stage to humans. It has a shallow bothria at the anterior end (arrow) and can vary in size from 5 mm to 3 cm in length